Case Report
Journal of Anaesthesia and Critical Care Case Reports | 2024 January-April; 10(1): 00-00

Anaesthesia in a Pregnant Female with Infective Spondylodiscitis Posted for Laminectomy with Posterior Instrumentation

Ashwin Mohan[1,2], Deepa Kane[1], Priti Devalkar[1]

Abstract

Introduction: Spondylodiscitis in pregnancy is an uncommon entity that can inadvertently hamper the pregnancy.

Case presentation: A 25-year-old primigravida in the middle of her third trimester presented with new-onset ascending paralysis due to infective spondylodiscitis. The compression of the spinal cord by virtue of spondylodiscitis demanded immediate surgical decompression. The indirect decompression of the spinal cord was successfully accomplished by performing laminectomy with posterior instrumentation while the anesthesiologists provided general anaesthesia, monitored, and maintained maternal and foetal safety. Anaesthetic methods employed include perioperative tocolytic cover, an induction of rapid sequence, aspiration prophylaxis, balanced analgesia, and appropriate maintenance of Mean Arterial Pressure, thereby ensuring maternal and foetal well-being.

Conclusion: A prompt surgical intervention and appropriate anaesthesia management resulted in successful decompression of the spinal cord with excellent recovery of paraplegia while avoiding maternal and foetal morbidity and mortality.

Keywords: Pregnancy, Laminectomy, Foetal monitoring, Patient positioning, Uteroplacental blood flow.

Introduction

Spondylodiscitis in pregnancy is a rare condition. If spondylodiscitis is associated with a progressive neurovascular deficit, the pregnant woman, regardless of gestational age, can be taken up for surgical intervention[1]. Though it is estimated that 1-2% of expectant women undergo non-obstetric surgeries, the literature on anaesthesia for neurosurgery in pregnant females has been under-documented [2].

This is documentation of the management of anaesthesia on a pregnant woman with infective spondylodiscitis undergoing decompression surgery.

Case Description

The 30-week-pregnant 25-year-old primigravida presented with bilaterally symmetrical lower limb paraparesis, which she developed over a period of ten days. The weakness was sudden in onset, progressive in nature, and it was associated with a lower back ache that had been radiating to bilateral lower limbs for the past two months. MR dorsal spine revealed infective spondylodiscitis involving D4-D5 vertebrae with severe spinal cord compression, most likely of tubercular aetiology. (Fig. 1, 2)

Preoperatively, the patient's vitals and airway evaluation were normal. Injection Hydroxyprogesterone 500 mg (tocolytic) was administered intramuscularly 12 hours before surgery. Prior to the surgery, the heart rate of the foetus was checked and documented using a hand-held Doppler.

A wedge was positioned under the right groin while the pregnant female was taken to the operating room. Aspiration prophylaxis included injection Ondansetron (0.1mg/kg) (slow IV), injection Metoclopramide (0.15mg/kg) (IV), and injection Pantoprazole (1 mg/kg) (IV). Vitals monitoring included 5-lead electrocardiography, invasive blood pressure monitoring, pulse oximetry, capnography, capillary blood sugar monitoring, and blood gas analysis.

Preoxygenation was done with 100 percent oxygen for 5 minutes, and the surgical induction of anaesthesia was done with injection Fentanyl (2μg/kg) (IV), injection Propofol (2 mg/kg) (IV) and injection Succinylcholine (2 mg/kg) (IV). Moreover, it was a rapid sequence. Intubation was done with a 6.5 mm cuffed endotracheal tube using a video laryngoscope. Maintenance of anaesthesia was with 50% Oxygen, 50% Nitrous oxide, Sevoflurane at 0.5 to 1% concentration, and injection Fentanyl (IV). After securing the arterial line, the subject was shifted to the left lateral position. (Fig. 3) The pressure points were carefully padded, and the abdominal lead guard concealed the gravid uterus.

Without the aid of fluoroscopy, an indirect decompression via laminectomy spanning D5 to D7 vertebrae and posterior instrumentation spanning D3 to D7 was completed in 6 hours. (Fig. 4, 5) With a blood loss of approximately 450 ml and a urine output of approximately 300 ml, the patient received 1200 ml of crystalloid and one pint of packed RBC containing 300 ml. The maternal hemodynamics were maintained throughout the surgery. The patient was returned to supine with a 15° left tilt at the end of the surgery. She

[1]Department of Anaesthesiology, Seth G.S. Medical College and K.E.M Hospital, Mumbai, Maharashtra, India.
[2]Department of Anaesthesiology, E.S.I.S Hospital, Worli, Mumbai, Maharashtra, India.
Address of Correspondence
Dr. Ashwin Mohan
Department of Anaesthesiology, Seth G.S. Medical College and K.E.M Hospital, Mumbai, Maharashtra, India.
Department of Anaesthesiology, E.S.I.S Hospital, Worli, Mumbai, Maharashtra, India.
E-mail: mohanashwin.93@gmail.com

Submitted: 18/07/2023; Reviewed: 11/08/2023; Accepted: 21/11/2023; Published: 10/01/2024

DOI: https://doi.org/10.13107/jaccr.2024.v10.i01.000

This is an Open Access article distributed under the terms of the Creative Commons Attribution Non-Commercial-Share Alike 4.0 License (http://creativecommons.org/licenses/by-nc-sa/4.0) which allows others to remix, tweak, and build upon the work non-commercially as long as appropriate credit is given and the new creation are licensed under the identical terms.

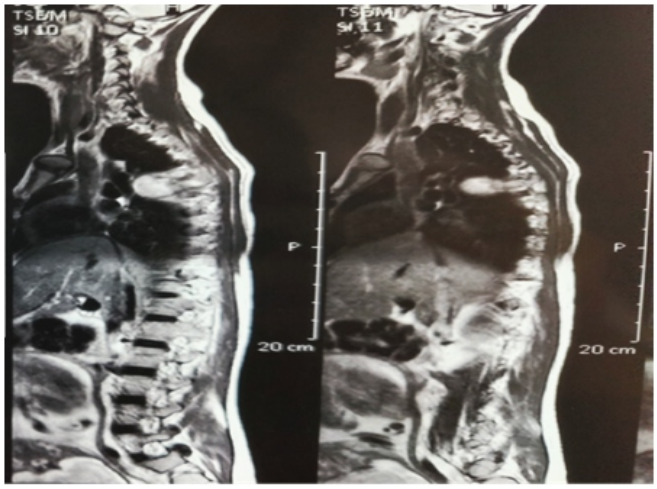

Figure 1: MR imaging of the whole spine in the sagittal section reveals Infective spondylodiscitis at D4-D5 vertebrae with right paravertebral soft tissue.

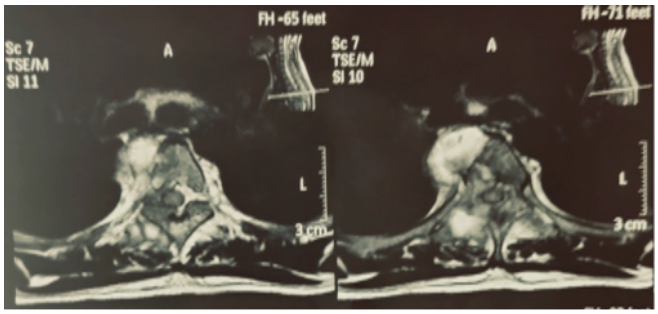

Figure 2: MR imaging of the whole spine in the transverse section reveals Infective spondylodiscitis extending into the anterior and posterior epidural spaces with severe spinal cord compression

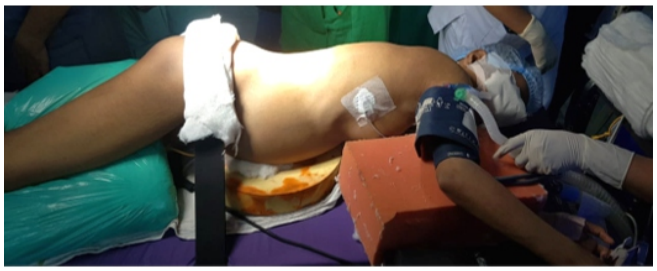

Figure 3: Left lateral decubitus position for surgical intervention with adequate padding.

Figure 4: Posterior instrumentation spanning vertebrae D3 to D7.

was extubated once the extubation criteria were met. Postoperatively, the patient was monitored in the ICU in the left lateral position, and the heart rate of the foetus was documented with a hand-held Doppler. Since the patient was a case of infective spondylodiscitis, placement of epidural catheter was avoided. For this reason, multimodal analgesia was used for post operative pain relief, which included Injection paracetamol (15 mg/kg) (I.V) 6 hourly, Injection Tramadol (1 mg/kg) (I.V) (8 hourly), and Tablet Pregabalin (75 mg) (P.O) 12 hourly.

Discussion

Spondylodiscitis with progressive neurodeficit during pregnancy is extremely rare, necessitating immediate surgical intervention. The basis of anaesthesia management was an amalgamation of neuro and obstetric anesthesiology. Numerous prospects, such as the participation of an interdisciplinary team, documentation of foetal heart rate monitoring, aspiration prophylaxis, use of tocolytics, maternal vital sign monitoring, surgical position, and good analgesia, were given priority. Our surgical team consisted of anesthesiologists, surgeons, obstetricians, and neonatologists. The chances of an emergency caesarean section were explained to the patient, and informed consent was obtained. As care was taken to lower the chance of foetal death and preterm delivery, meticulous care was taken to maintain maternal hemodynamic stability throughout the perioperative period [3].

A pregnant patient with a viable foetus should undergo simultaneous evaluation of the heart rate of the foetus and contraction monitoring at least once before and after the procedure to verify and document the well-being of the foetus and the absence of uterine contractions. Moreover, the update goes on to state that intraoperative foetal monitoring can be done, provided that it is physically feasible to perform [1]. In our case, we were not able to perform intraoperative foetal monitoring because of the use of the abdominal lead guard; nonetheless, simultaneous verification of the foetal heart rate and contraction monitoring were done before and after the procedure.

Supine posture at the gestational age of 20 weeks compresses the descending aorta and vena cava and this could lead to a 20% reduction in venous return. After the gestational age of 20 weeks, the patient should be made to lie in the left lateral decubitus position or supine position while a wedge is placed under the right hip joint, thereby shifting the uterus to the left, and avoiding supine hypotension syndrome [5]. Our patient was escorted to the surgical theatre in the left lateral decubitus position, and the intubation was done with the patient lying in the supine position while a wedge was placed under the right hip joint.

Pregnant patients are always considered to have a full stomach [6]. In

fact, the chances of aspiration may rise as pregnancy progresses because of the raised intra-abdominal pressure and decreased pressure on the lower esophageal sphincter, indicating the necessity for the application of cricoid pressure [7]. Therefore, aspiration prophylaxis is inevitable. Our aspiration prophylaxis included drugs such as injection Metoclopramide and injection Pantoprazole half an hour prior to surgery, along with the application of cricoid pressure during induction.

The intraoperative position should be chosen on the basis of gestational age, location, and the dimensions of the lesion. After 12 weeks of pregnancy, the left lateral posture is preferred to avoid aortocaval compression [8]. Regardless of position or operating table, careful attention should be paid to ensuring that the abdomen remains free throughout the procedure [9]. Our patient presented herself in the middle of the third trimester, so we opted to go ahead with the left lateral decubitus position.

Pain during surgical intervention can activate the central nervous system, which in turn stimulates NMDA and other excitatory receptors in the foetal brain. This could result in changes in pain sensitivity and processing and abnormalities in neurodevelopment, behaviour, and cognitive functions that manifest later in childhood [10]. Moreover, a light plane of anaesthesia may result in a surge of catecholamines, which may compromise uteroplacental perfusion [11]. Therefore, our main objective was to attenuate pain and stress throughout the procedure.

No anaesthetic drug has been declared to have teratogenic effects in humans [1]. We used intravenous opioids, acetaminophen, muscle relaxants, and inhalational agents at appropriate therapeutic doses.

Since maternal hypotension is known to reduce uterine blood flow, the Mean Arterial Pressure was strictly kept above 70 mmHg using beat-to-beat blood pressure monitoring via an arterial line [12]. Besides maintaining adequate oxygenation and normocarbia, glucose-free isotonic intravenous fluid, blood transfusion, and hourly urine output monitoring were also done to maintain maternal hemodynamic stability.

Conclusion

In conclusion, spinal surgery on an expectant female can be done in a considerably safe way by providing an appropriate surgical position and analgesia while maintaining maternal hemodynamics.

Clinical message

> Perioperative tocolytics, foetal heart rate monitoring, and uterine contraction monitoring are required to prevent and detect uterine stimulation and thus maintain foetal well-being.

> The patient should be escorted to the operating table in left lateral position and the induction of general anaesthesia should be done in supine position with a wedge under the right groin.

> To ensure a pressure free abdomen, left lateral decubitus position is preferred in the second and third trimester.

> General anaesthesia should include aspiration prophylaxis with Sellick's manoeuvre, appropriate dose of anaesthetic agents.

> Avoidance of hypoxia and hypo- or hypercarbia while maintaining a MAP above 70 mmHg is a key factor in monitoring.

Declaration of patient consent: The authors certify that they have obtained all appropriate patient consent forms. In the form, the patient has given his/her consent for his/her images and other clinical information to be reported in the Journal. The patient understands that his/her name and initials will not be published, and due efforts will be made to conceal his/her identity, but anonymity cannot be guaranteed.

Conflict of interest: Nil **Source of support:** None

References

1. ACOG Committee Opinion No. 775: Nonobstetric Surgery During Pregnancy. Obstet Gynecol. 2019 Apr;133(4):e285-e286. doi: 10.1097/AOG.0000000000003174. PMID: 30913200.
2. Kuczkowski KM. Nonobstetric surgery in the parturient: anaesthetic considerations. J Clin Anesth. 2006 Feb;18(1):5-7. doi: 10.1016/j.jclinane.2005.11.003. PMID: 16517324.
3. Ravindra GL, Madamangalam AS, Seetharamaiah S. Anaesthesia for non-obstetric surgery in obstetric patients. Indian J Anaesth. 2018 Sep;62(9):710-716. doi: 10.4103/ija.IJA_463_18. PMID: 30237597; PMCID: PMC6144550.
4. Kort B, Katz VL, Watson WJ. The effect of nonobstetric operation during pregnancy. Surg Gynecol Obstet. 1993 Oct;177(4):371-6. PMID: 8211581.
5. Heidemann BH, McClure JH. Changes in maternal physiology during pregnancy. BJA CEPD Reviews [Internet]. Elsevier BV; 2003 Jun;3(3):65–68. Available from: http://dx.doi.org/10.1093/bjacepd/mkg065
6. Shetti AN, Dhulkhed VK, Gujarati A, Swetha GS. Anaesthetic management of a pregnant patient with pseudo-pancreatic cyst for cysto-gastrostomy. Anesth Essays Res. 2014 Jan-Apr;8(1):89-92. doi: 10.4103/0259-1162.128920. PMID: 25886112; PMCID: PMC4173600.
7. Melnick DM, Wahl WL, Dalton VK. Management of general surgical problems in the pregnant patient. Am J Surg. 2004 Feb;187(2):170-80. doi: 10.1016/j.amjsurg.2003.11.023. PMID: 14769301.
8. Vougioukas VI, Kyroussis G, Gläsker S, Tatagiba M, Scheufler KM. Neurosurgical interventions during pregnancy and the puerperium: clinical considerations and management. Acta Neurochir (Wien). 2004 Dec;146(12):1287-91; discussion 1291-2. doi: 10.1007/s00701-004-0354-9. Epub 2004 Aug 30. PMID: 15338336
9. Abou-Shameh MA, Dosani D, Gopal S, McLaren AG. Lumbar discectomy in pregnancy. Int J Gynaecol Obstet. 2006 Feb;92(2):167-9. doi: 10.1016/j.ijgo.2005.09.028. Epub 2005 Dec 5. PMID: 16336971.
10. Cheek TG, Baird E. Anesthesia for nonobstetric surgery: maternal and fetal considerations. Clin Obstet Gynecol. 2009 Dec;52(4):535-45. doi: 10.1097/GRF.0b013e3181c11f60. PMID: 20393407.
11. Ní Mhuireachtaigh R, O'Gorman DA. Anaesthesia in pregnant patients

for nonobstetric surgery. J Clin Anesth. 2006 Feb;18(1):60-6. doi: 10.1016/j.jclinane.2004.11.009. PMID: 16517336.

12. Kunitz O, Rossaint R. Anästhesie in der Schwangerschaft [Anesthesia during pregnancy]. Chirurg. 2005 Aug;76(8):737-43. German. doi: 10.1007/s00104-005-1074-2. PMID: 16047202.

How to Cite this Article

Mohan A, Kane D, Devalkar P | Anaesthesia in a Pregnant Female with Infective Spondylodiscitis Posted for Laminectomy with Posterior Instrumentation | Journal of Anaesthesia and Critical Care Case Reports | January-April 2024; 10(1): 00-00.