Technical Note
Journal of Anaesthesia and Critical Care Case Reports 2016 Jan-Apr;2(1):25-28

Infracoracoid Vertical Approach for Infraclavicular Brachial Plexus Block and Neurostimulation – Anatomical and Technical Description

Sandeep Diwan[1]

Abstract

Intoduction: Infraclavicular blocks are been described long back but coracoid vertical approach is a relatively new approach. It has advantage of easily identifiable landmarks and easy to perform. This article focusses on the anatomical and technical issues and describes the procedure in details..

Keywords: Fascia iliaca compartment block, Regional anesthesia, Postoperative pain.

Introduction

Infraclavicular blocks are been described long back but coracoid vertical approach is a relatively new approach. It has advantage of easily identifiable landmarks and easy to perform. This article focusses on the anatomical and technical issues and describes the procedure in details.

The Infraclavicular approach was first described by Labat in 1922 [1].

The coracoid infraclavicular approach to neural blockade of the upper extremity provides several advantages as compared to axillary and supraclavicular brachial plexus block.

The anatomic surface landmarks are easy to identify, the head and arm may be in any position for the block, the technique is relatively easy to perform using either a nerve stimulator or ultrasound guidance.

The coracoid infraclavicular technique, originally described by Whiffler in 1981 [2], has become popular because of relatively easily identified anatomic landmarks, reliable distribution of neural blockade, and low risk of respiratory complications, such as phrenic nerve blockade and pneumothorax [3].

Infraclavicular Anatomy

Below the clavicle the anterior divisions of the superior and middle trunks form the lateral cord. The posterior divisions of all 3 trunks form the posterior cord, and the anterior division of the inferior trunk forms the medial cord. The cords are according to their relationship to the axillary artery. They are all enclosed in well defined neurovascular sheath (Fig 1). Sheath enclosing brachial cordsThe cords pass over the first rib close to the dome of the lung and continue under the clavicle immediately posterior to the subclavian artery.

The lateral cord branches into Musculocutaneous nerve (C4, C5, C6, and C7), Lateral root of the Median nerve (C5, C6, and C7), Lateral pectoral nerve (C5, C6, and C7).

The Medial Cord forms the Medial root of the median nerve and continues as the ulnar nerve along the medial and anterior surface of the axillary artery. It also gives following branches - Median pectoral nerve (C8, T1), Medial brachial cutaneous nerve (T1) and Medial antebrachial cutaneous nerve (C8, T1).

The Posterior cord gives following branches - Axillary nerve (C5 and C6), Radial nerve (C5, C6, C7, C8, and T1), Upper subscapular nerve (C5 and C6), Thoracodorsal nerve (C6, C7, and C8), Lower subscapular nerve (C5 and C6).

The medial and lateral roots (lateral cord) join to form the the median nerve which continues along the posterior and lateral surface of the axillary artery.

Axillary nerve:The axillary nerve supplies the shoulder joint, the surgical neck of the humerus, the deltoid, and the teres minor muscles before ending as the superior lateral brachial cutaneous nerve. The axillary nerve is separated from the cord close to the coracoid process. This is commonly encountered during the infraclavicular block.

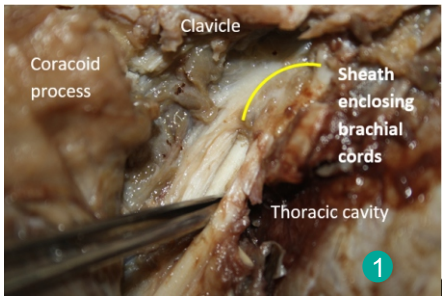

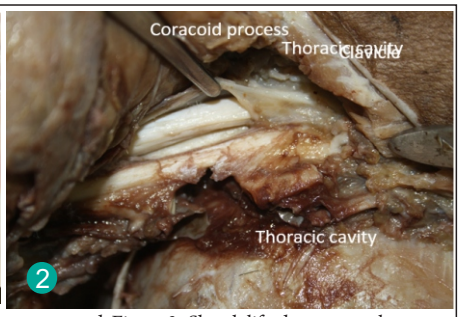

Figure 1: Infraclavicular area: cords exposed after sheath was opened. Figure 2: Sheath lifted to expose the brachial cord.Cadaveric dissection – Sandeep Diwan Department of Anatomy, Government Medical College Miraj

[1]Department of Anaesthesiology, Sancheti hospital Pune, India.

Address of Correspondence
Dr Sandeep Diwan
Department of Anaesthesiology, Sancheti hospital Pune, India.
Email: sdiwan14@gmail.com



Dr. Sandeep Diwan

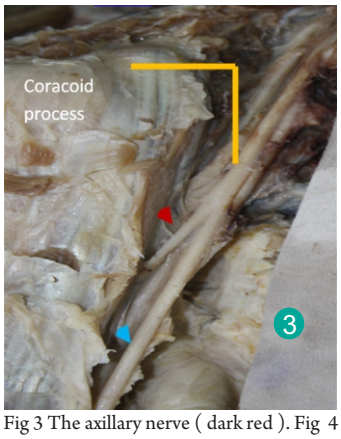

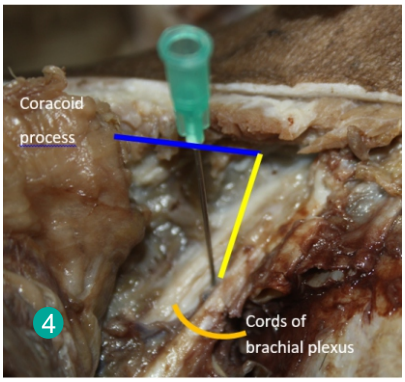

Fig 3 The axillary nerve (dark red). Fig 4 Anatomical landmark for infracoracoid vertical approach. Cadaveric dissection – Sandeep diwanDepartment of Anatomy, Government Medical College Miraj

The radial nerve (blue) continues along the posterior and inferior surface of the axillary artery.

Indications for Infraclavicular Block

1. Posterior approach to humerus.
2. Posterior approach to elbow.
3. Medial and lateral approaches to elbow.
4. Surgeries on the forearm.
5. Surgeries on the wrist.
6. Surgeries on the hand and fingers.

Approaches to Infraclavicular Brachial Plexus.

There are many approaches to the infraclavicular brachial plexus. Prominent of these are :

a. Raj approach to Infraclavicular [4]

b. Sims modification of Infraclavicular block [5]

c. Coracoid block [2]

d. Vertical Infraclavicular block [6-8]

e. Infracoracoid technique

At the point 2 cm medial and 2 cm caudad to the tip of the coracoid process, the direct posterior placement of a needle would contact the cords of the brachial plexus where they surround the second part of the axillary artery [9].

Technique: Coracoid infraclavicular

The patient lies supine with the head turned away from the arm to be anesthetized. The arm lies parallel to the trunk (adducted) and or is allowed to rest comfortably on the abdomen. This is particularly necessary in patients with forearm and elbow injuries.

The point of puncture is 2 cm medial and 2 cm inferior to the lateral tip of the coracoid process.

The needle was placed according to the anatomical landmarks mentioned and the pectoral flaps were reflected after careful dissection. The needle was in the perineural sheath [Fig 4].

Steps to vertical infracoracoid block.

1. Palpation of coracoid process (Fig 5).
2. Needle insertion – 2cm medial and 2 cm inferior to coracoid process (Fig 6)
3. Needle insertion is vertical;two pops felt as needle penetrates the pectoralis major and minor (Fig 7)

Check Posterior cord: Extension of the Interphalangeal joint of the thumb and fingers or only extension of the metacarpophalangeal joint of the index finger, thumb (Fig 8,9).

Check Medial cord: Flexion of the Interphalangeal joint of the thumb with extension of the metacarpophalangeal joint of the index finger.The PNS is fine tuned at 0.3ma to produce the same response as observed earlier. The needle is then held firmly and an assistant injects the drug.

Ideal end points –

Multineurostimulation is the norm in the infraclavicular blocks. A single response either a posterior cord preferentially of a medial cord response is obtained.

Stimulation of the posterior cord predicts successful infraclavicular block [10].

Failure rates: 5.8% for posterior cord, 28.3% for lateral, and 15.4% for medial.

Why target the posterior cord?

The posterior cord appears to lie central to both the lateral and medial cords. A "central" location is considered because the relative positions of the cords change as they twist around the axillary artery [11].

Borgeat and Coll reported a 97% rate of

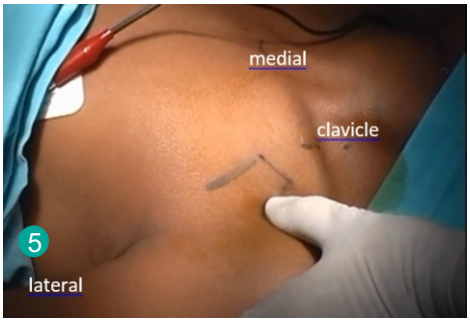

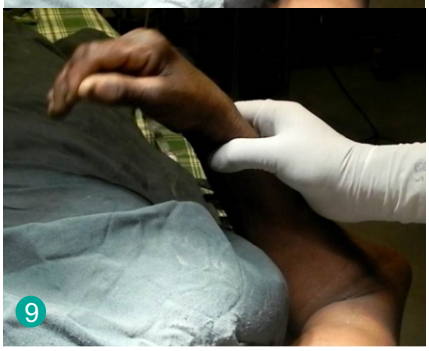

Figure 5: Palpation of coracoid process. Figure 6: Needle insertion – 2cm medial and 2 cm inferior to coracoid process. Figure 7: Needle insertion is vertical;two pops felt as needle penetrates the pectoralis major and minor. Inner curved line – thoracic cage. Outer dotted line – possibility of thoracic cage expansion in emphysematous chest. Figure 8: Extension of metacarpophalangeal joint. Figure 9: Flexion of metacarpophalangeal joint

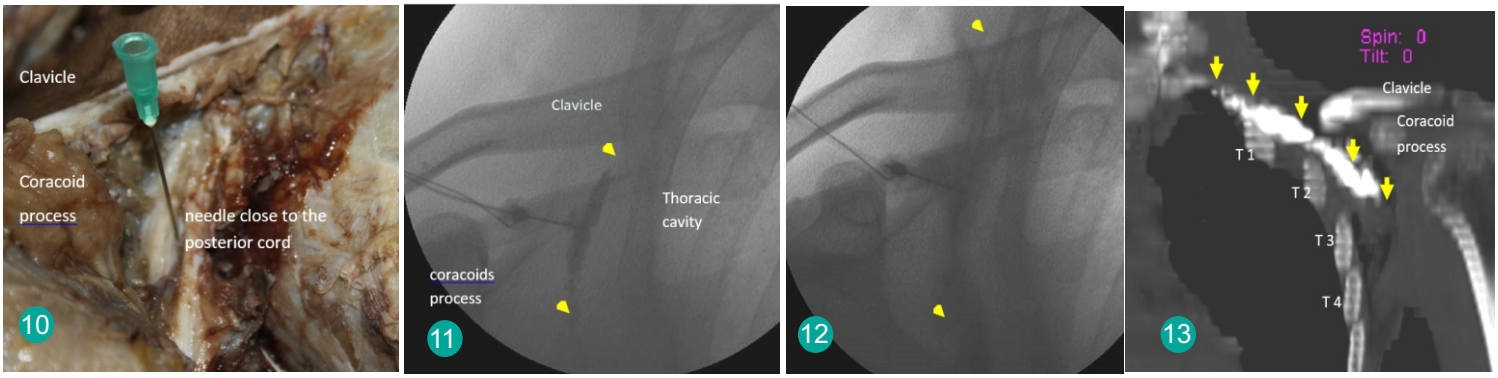

Fig 10 Needle placement close to the posterior cord. Fig 11 Cephalo-caudal spread of contrast. Contrast injected takes a direction cephalad and caudad to needle insertion. Fig 12 Cephalad spread of the contrast after 10ml LA. Fig 13 CT Contrast of the infraclavicular flow.

Infraclavicular block success when nerve stimulation elicited a distal response consistent with central placement [12].
Note the compactness of the cords in the infraclavicular area (Fig 10). The placement of the needle is close to the posterior cord, will allow even spread of the local anaesthetic along the perineural compartments.

Contrast studies - Posterior cord stimulation.
A posterior cord response was obtained with needle directed 30d cephalad after it was inserted vertical. Thoracic cavity
Contrast injected takes a direction cephalad and caudad to needle insertion. Injecting 10 ml more in 5 ml aliquots more cephalad spread toward the supraclavicular area is visible. As the contrast and the drug are injected a more cephalad spread is identified.
The contrast reaches just below the clavicle with 5ml and with 10ml a well defined railway track appearance is observed with the spread in the supraclavicular area (Fig 11 and 12).
The CT contrast depicts the flow of the drug across the perineural sheath (Fig 13).
The spread is from the injection point both cephalad and caudad. Cephalad it reaches the interscalene area and the lower cervical roots and distally the axillary terminal nerves.
The spread is consistent with the description of the perineural sheath from the cervical roots to the axillary area (Fig 13 and 14).T 4 T 3 The spread of the contrast is shaped fusiform (Fig 14) with maximum dilatation at the point of injection and tapering towards ends (Fig 14). The infraclavicular area is a highly compliant space.
The single posterior cord neurostimulation depicting all three cords stained by the injected contrast (Fig 15).
The cords are depicted in relation to the axillary artery. Anterior is the lateral cord just below the pectoralis major and the minor (Fig 15). Superior is the medial cord and posteroinferior is the posterior cord (Fig 15).
Posterior cord stimulation allows the drug to be in the centre of the plexus in the infraclavicular area [13].
Contrast studies - Medial cord stimulation.
The needle is inserted vertical for the infraclavicular block. Note the needle tip deviation medially to elicit a medial cord response - flexion of the MCP and wrist joints. On injection, the contrast spread occurs more distally towards the axillary fossa (Fig 16). Though a small spread does occur proximally (Fig 17).

Optimal response.
In a prospective study [14,15] patients underwent emergency upper limb surgery using double stimulation infraclavicular block.
The success rate was 96% for the radial response group, 89% for the median response group, and 90% for the ulnar response group.
Note: Obtain posterior cord (radial response) for maximum efficacy of infraclavicular block. A medial cord response if obtained on first occasion, there is no need to search for the posterior cord response. At times a dual response is obtained (radial and median) with slight needle tip manipulations.

Optimal drug volume and concentration.
Volume of local Anaesthetic.
At Posterior cord response - 30ml, 1.5% Xylocaine 10ml and 0.5% Bupivacaine 20ml for prolonged procedures.
At Medial cord response - 40ml, 1.5%

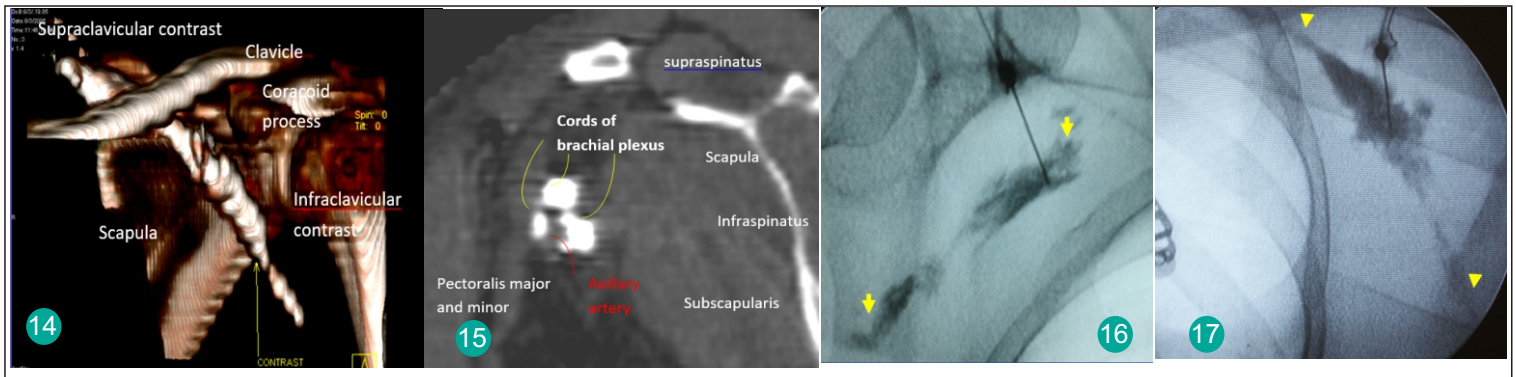

Figure 14. A three dimensional view of the infraclavicular spread of the contrast. Figure 15. Coronal plane depicting the three cords stained with a single injection. Figure 16 caudad flow after medial cord stimulation.. Figure 17 Medial cord stimulation with contrast spread.

Xylocaine 10ml and 0.5% Bupivacaine 30ml for prolonged procedures.
One study [16] compared three groups randomised to receive 40 mL fixed volume of local anesthetic mixture administered via a modified coracoid approach to the infraclavicular brachial plexus using a double-stimulation technique. The effect of the block to the proximal part of the arm was very adequate as reflected by tolerance to surgery on this area and/or by tourniquet tolerance of 98-99%.This implies the anesthetic block of axillary nerve and musculocutaneous nerve. The best results were obtained with a LA mixture 1.5% plain lidocaine and 0.37% bupivacaine with 1:2 Lac.

References

1.Labat G. Brachial plexus block: details of technique. Anesth Analg 1927;6:81–2.

2.Whiffler K. Coracoid block—a safe and easy technique. Br J Anaesth 1981;53:845–8.

3.Wilson JL, Brown DL, Wong GY, Ehman RL, Cahill DR. Infraclavicular brachial plexus block: parasagittal anatomy important to the coracoid technique. Anesth Analg 1998;87: 870–3.

4.Raj PP, Montgomery SJ, Nettles D, Jenkins MT. Infraclavicular brachial plexus block—a new approach. Anesth Analg 1973;52:897–904

5.Sims JK. A modification of landmarks for infraclavicular approach to brachial plexus block. Anesth Analg 1977;56:554–5

6. Moayeri N, Renes S, van Geffen GJ, Groen GJ. Vertical infraclavicular brachial plexus block: needle redirection after elicitation of elbow flexion. Reg Anesth Pain Med. 2009 May-Jun;34(3):236-41.

7.Renes S, Clark L, Gielen M, Spoormans H, Giele J, Wadhwa A. A simplified approach to vertical infraclavicular brachial plexus blockade using hand-held Doppler. Anesth Analg. 2008 Mar;106(3):1012-4

8.Kilka HG, Geiger P, Mehrkens HH. Infraclavicular vertical brachial plexus blockade. A new method for anesthesia of the upper extremity. An anatomical and clinical study. Anaesthesist 1995;44:339–44

9.Neuburger M, Kaiser H, Rembold-Schuster I, Landes H. Vertical infraclavicular brachial-plexus blockade. A clinical study of reliability of a new method for plexus anesthesia of the upper extremity. Anaesthesist 1998;47:595–9

10.Rettig HC, Gielen MJ, Boersma E, Klein J. A comparison of the vertical infraclavicular and axillary approaches for brachial plexus anaesthesia.

Acta Anaesthesiol Scand 2005;49:1501–8

11. Jack L. Wilson,David L. Brown, Gilbert Y. Wong, Richard L. Ehman.and Donald R. Cahill. Infraclavicular Brachial Plexus Block: Parasagittal Anatomy: Important to the Coracoid Technique. Anesth Analg 1998 87 870-3

12. Harish Lecamwasam, James Mayfield, Laura Rosow, Yuchiao Chang, Christopher Carter, and Carl Rosow.Stimulation of the Posterior Cord Predicts Successful Infraclavicular Block Anesth Analg 2006;102:1564-1568

13.Sala-Blanch X, Carrera A, Morro R, Llusa M. Interpreting infraclavicular motor responses to neurostimulation of the brachial plexus: from anatomic complexity to clinical evaluation simplicity. Reg Anesth Pain Med 2004;29:618–20.

14.Borgeat A, Ekatodramis G, Dumont C. An evaluation of the infraclavicular block via a modified approach of the Raj technique. Anesth Analg 2001;93:436–41.

15.Rodríguez J, Taboada M, Oliveira J, Ulloa B, Bárcena M, Alvarez J .Single stimulation of the posterior cord is superior to dual nerve stimulation in a coracoid block.Anesth Analg 2007;104:448-451

16. Jaime Rodríguez, , M. Bárcena, , M. Taboada-Muñiz, J. Lagunilla, J. Álvarez. A Comparison of Single Versus Multiple Injections on the Extent of Anesthesia with Coracoid Infraclavicular Brachial Plexus Block Anesth Analg 2004;99:1225-1230.

Conflict of Interest: Nil
Source of Support: None

How to Cite this Article

Diwan S. Infracoracoid Vertical Approach for Infraclavicular Brachial Plexus Block and Neurostimulation – Anatomical and Technical Description . Journal of Anaesthesia and Critical Care Case Reports Jan-April 2016; 2(1):25-28.